

# Development of a Novel Early Intervention Stabilization for Abdominal Aortic Aneurysms

Timothy J. Madsen<sup>1</sup>, Amanda Sohn<sup>1</sup>, Kyle Stansbury<sup>1</sup>, Emily Griffith<sup>1</sup>, Kate Johnson<sup>1</sup>, Rachel Bardot<sup>1</sup> and Dale M. Groth<sup>2</sup>  
<sup>1</sup>Altasciences Preclinical Columbia, MO, United States, <sup>2</sup>Dale Groth Preclinical Consulting LLC, MN, United States

Abstract ID# 3348

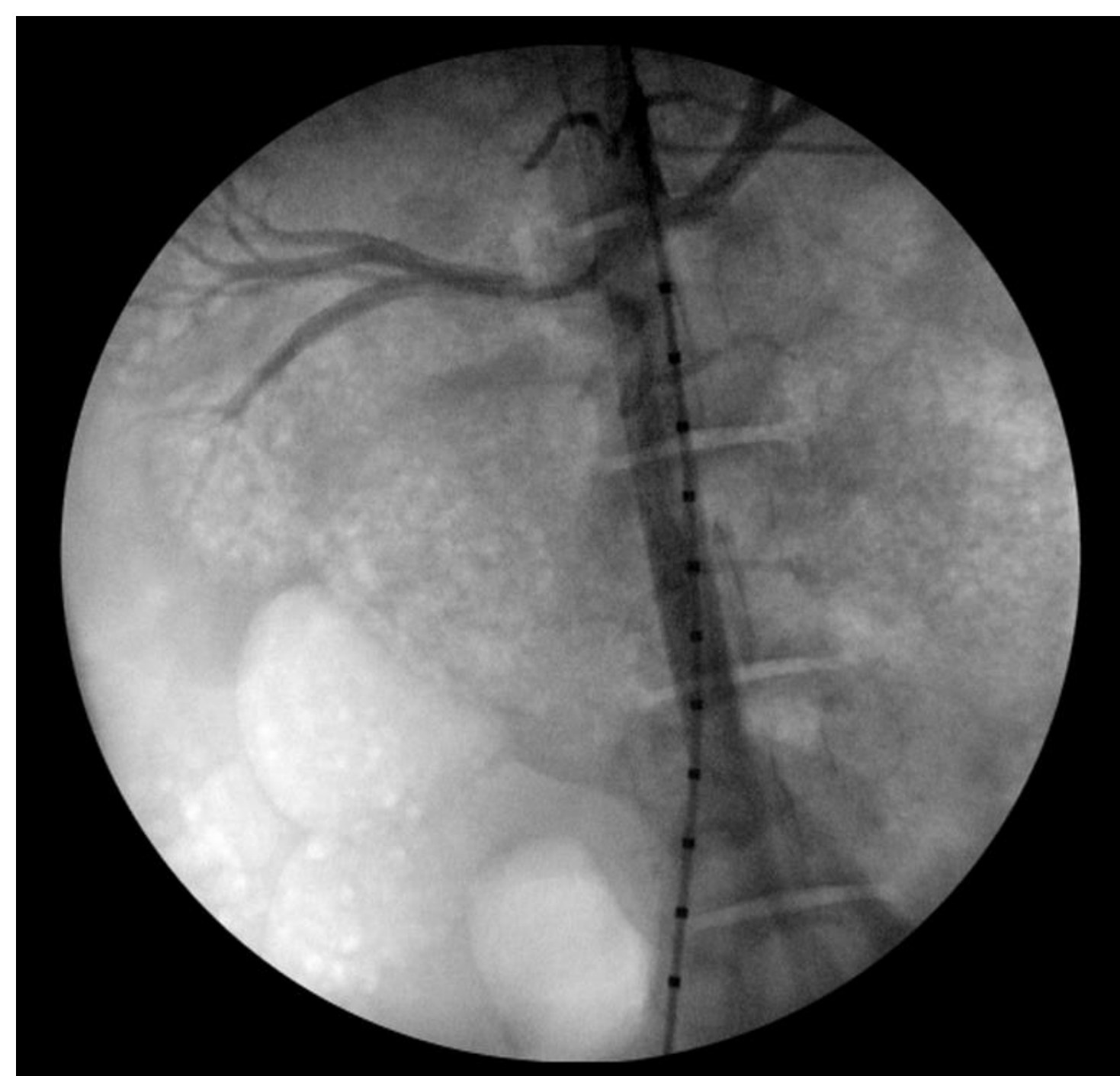Click here to listen to the recorded poster presentation

## INTRODUCTION

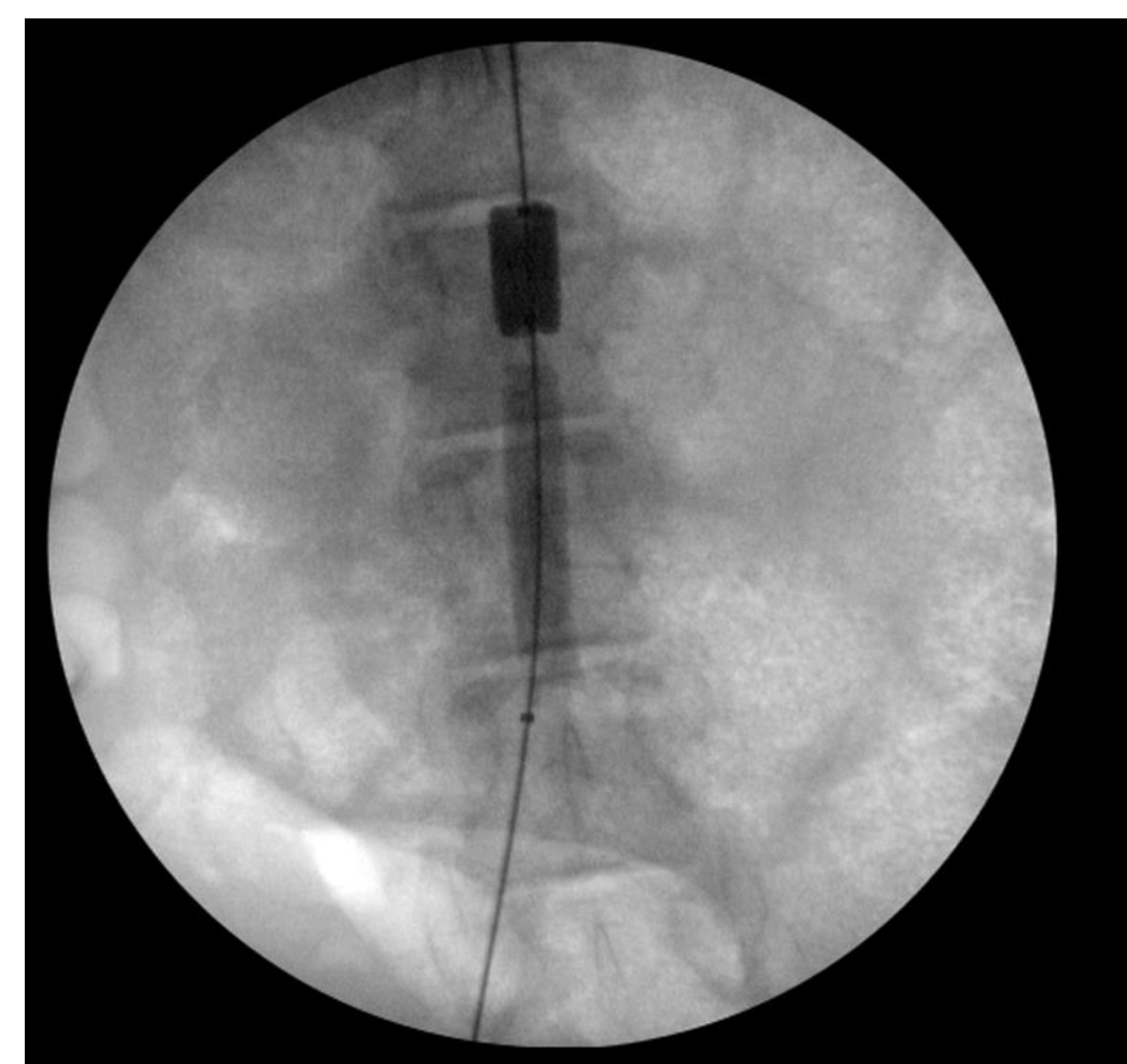
An abdominal aortic aneurysm (AAA) is defined as a focal dilation of the blood vessel for the original artery; specifically, an aortic diameter at least one and one-half times the normal diameter at the level of the renal arteries (approximately 2.0 cm). Diagnoses of AAAs typically occur once aneurysms are over 3.0 cm with surgical or endovascular repair generally considered once a diagnosed aneurysm reaches 5.5 cm or larger. The risk of rupture increases markedly as the aneurysm diameters increase and repair is indicated when the risk of rupture exceeds the risks associated with the repair procedure itself. In the current study, a proprietary catheter is being developed to be used in combination with a stabilizing agent for the treatment of aneurysms between 3.5 and 5.0 cm, which currently have no proven treatment other than “watch and wait.” The stabilizing agent contains pentagalloyl glucose (PGG), a chemical known to bind and stabilize proteins in the aortic wall. The purpose of the study was to determine the local and systemic toxicity, as well as pharmacokinetics following a single, localized intra-aortic infusion.

## METHODS

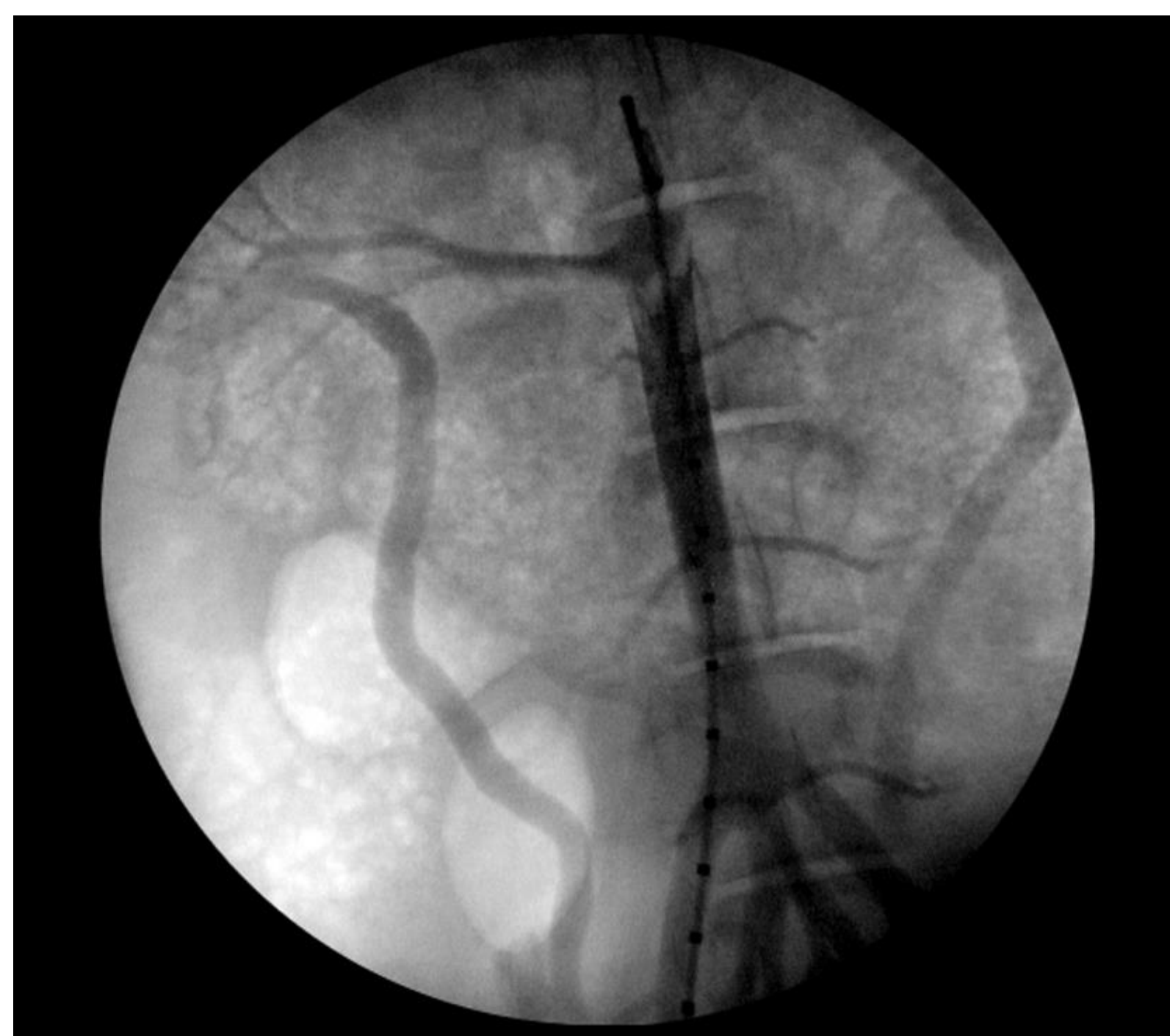- 18 Yucatan™ miniature swine/sex/group (n=144 total) at 3-, 7-, 30-, 60-, 90-, and 270-days post treatment time points.
- Under anesthesia, stabilizing solution was administered at 1x, 3x, or 6x the therapeutic dose level compared to a vehicle control, using a novel dual balloon catheter system.



**Figure 1.** Using fluoroscopy, a catheter was guided into the abdominal aorta via the femoral artery. An angiogram was performed prior to dose administration and aortic dimensions were obtained.



**Figure 2.** The occlusion and drug delivery balloons were inflated, followed by administration of the stabilizing agent, then removal of the catheter. The femoral artery was ligated, and the incision closed using standard techniques.



**Figure 3.** Using fluoroscopy, a catheter was guided into the abdominal aorta via the carotid aorta prior to scheduled termination and aortic dimensions were obtained. An antegrade angiogram was performed to avoid interaction with the treated aorta/dose site.

### Endpoints evaluated:

- Invasive blood pressure
  - Angiography
  - Thrombogenicity
  - Physical examinations
  - Body weight
  - Food evaluation
  - Detailed clinical observations
  - Ophthalmology
  - Hematology
  - Coagulation
  - Serum chemistry
  - Urinalysis
  - Histopathology
  - Stabilizing agent's plasma and tissue concentrations over time at multiple time points
- At necropsy, gross observations and organ weights were recorded with selected tissues collected for microscopic evaluation on days 3, 7, 30, 60, 90, and 270 post-treatment.
  - Tissue concentrations from select tissues were determined from each of these cohorts for pharmacokinetic evaluation.

## RESULTS

- No stabilizing agent-related deaths.
- Surgical method resulted in a dwell time in the bloodstream ranging from 19 to 55 minutes and was assessed as a 0 for thrombogenicity (little or no adherent material) for all study animals.
- No related effects found in any of the safety endpoints: organ weights, macroscopic or microscopic findings.
- Refer to **Table 1** for the microscopic evaluation of the treated aortas. The observed neointima formation and intimal injury was related to the instrumentation manipulation during catheter insertion/removal on day 1.
- There was no effect on blood pressure or aortic dimensions, as assessed by angiography.
- Systemic exposure of stabilizing agent was low.
- Plasma levels were highest at the first sampling time point and, depending on dose level, fell to baseline within 24 to 48 hours post-treatment.
- Tendency for higher systemic exposure in females compared to males.
- Uptake of a drug into non-target organs was observed to be dose-dependent and transient.
- Based on the absence of adverse findings, locally or systemically, a no-observed-adverse-effect-level (NOAEL) was determined to be the highest dose delivered.

**Table 1.** Microscopic Evaluation of the Treated Aortas

The microscopic evaluation findings for treatment areas (aortas) are summarized below.					
Cohort ID	Parameter	Males		Females	
		Group 1 (Vehicle) Mean ± SD	Group 4 (High Dose) Mean ± SD	Group 1 (Vehicle) Mean ± SD	Group 4 (High Dose) Mean ± SD
3-Day	Injury Score	0.4 ± 0.5	0.1 ± 0.3	0.0 ± 0.0	0.1 ± 0.3
	Neointima	0.6 ± 0.5	0.4 ± 0.5	0.6 ± 0.5	0.0 ± 0.0
	Neointimal Maturity	0.6 ± 0.5	0.4 ± 0.5	0.6 ± 0.5	0.1 ± 0.3
30-Day	Injury Score	0.3 ± 0.5	0.1 ± 0.3	0.1 ± 0.3	0.2 ± 0.4
	Neointima	0.7 ± 0.5	0.7 ± 0.5	0.6 ± 0.5	0.9 ± 0.3
	Neointimal Maturity	1.8 ± 1.4	1.8 ± 1.4	1.7 ± 1.6	2.3 ± 1.0
60-Day	Injury Score	0.1 ± 0.3	0.0 ± 0.0	0.1 ± 0.3	0.1 ± 0.3
	Neointima	1.0 ± 0.0	0.7 ± 0.5	1.0 ± 0.0	0.7 ± 0.5
	Neointimal Maturity	3.0 ± 0.0	1.7 ± 1.3	3.0 ± 0.0	2.0 ± 1.5
90-Day	Injury Score	0.0 ± 0.0	0.1 ± 0.3	0.2 ± 0.4	0.1 ± 0.3
	Neointima	1.0 ± 0.0	1.0 ± 0.0	1.0 ± 0.0	1.0 ± 0.0
	Neointimal Maturity	3.0 ± 0.0	3.4 ± 0.5	3.0 ± 0.0	3.3 ± 0.5
270-Day	Injury Score	0.1 ± 0.3	0.4 ± 0.5	0.3 ± 0.5	0.1 ± 0.3
	Neointima	1.1 ± 0.3	1.0 ± 0.0	0.9 ± 0.3	1.0 ± 0.0
	Neointimal Maturity	3.9 ± 0.3	3.8 ± 0.4	3.4 ± 1.3	4.0 ± 0.0

## DEVICE PERFORMANCE AND ASSESSMENT

The device was evaluated and scored (1=poor and unacceptable, 2=fair and acceptable; 3=good and acceptable or 4=very good and acceptable) for the following parameters: compatibility between components, trackability, pushability, positioning, and withdrawal (force and feel).

In general, the surgical team and interventional consultants evaluated the performance criteria of the device as very good/acceptable for all categories except withdrawal (force and feel) which was scored from good/acceptable to very good/acceptable. Overall, the performance of the device met all criteria endpoints with no defects, kinks, or loss of components for the device and no occlusion/stabilizer balloon failure, dissection, or perforation with few exceptions/findings, including minor leaks in the occlusion balloon or slow to deflate, stabilizer balloon failure to inflate, slipped or ruptured.

## CONCLUSION

The endovascular procedure was determined to be successful in this 9-month Yucatan™ miniature swine study resulting in no overt toxicity, no histopathological findings, and no thrombosis observed. Based on the preclinical safety data from this study, this endovascular treatment warrants further evaluation in a randomized, controlled clinical trial to determine if it is appropriate as an early intervention option for patients with small to mid-sized abdominal aortic aneurysms (3.5 to 5.0 cm).